

Safety and Efficacy of an Autologous Blood Clot Product (RD1) in the Management of Texas 1A or 2A Neuropathic Diabetic Foot Ulcers: A Prospective, Multicenter, Open Label Pilot Study

Author(s): Robert J. Snyder, DPM, MSc, CWS; Maria A. Kasper, DPM; Keyur Patel, DO; Marissa J. Carter, PhD, MA; Igal Kushnir, MD5; Alon Kushnir, BSc; and Thomas E. Serena, MD

Affiliations:¹Barry University School of Podiatric Medicine, Miami Shores, FL; ²Martin Foot and Ankle, York, PA; ³Armstrong County Memorial Hospital, Kittanning, PA; ⁴Strategic Solutions, Inc, Cody, WY; ⁵RedDress Ltd, Pardes-Hanna, Israel; and ⁶SerenaGroup, Inc, Cambridge, MA

Objective. This pilot study evaluated the RD1 efficacy in terms of complete wound healing rates as well as its safety in terms of the occurrence of adverse events (AEs) when applied to chronic neuropathic diabetic foot ulcers (DFUs).

Materials and Methods. Participants were chosen from patients with DFUs visiting the wound care clinic. Up to 10 mL of blood drawn from each participant was mixed with coagulation reagents and injected into the product’s clotting tray. Within 12 minutes, the blood clot product was formed, applied to the single DFU of each participant, and covered with primary and secondary dressings. Patients received up to 12 blood clot product applications every 5 to 21 days for up to 12 weeks.



Fig. 1: The coagulating blood is injected into the clotting tray using moderate pressure

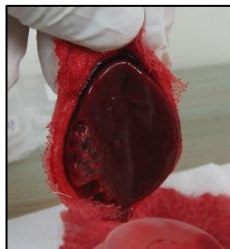

Fig. 2: The blood clot product is formed after 10 min in the clotting tray and removed, using both hands, by gently grabbing it from its rim.

Results. Twenty patients were enrolled and analyzed in the intent-to-treat (ITT) population and 18 were analyzed in the per-protocol (PP) population. The proportion of wounds healed in the ITT and PP populations was 13 out of 20 (65%) and 13 out of 18 (72.2%), respectively. Percentage area reduction (PAR) for the ITT population at 4 and 12 weeks was 61.6% and 67.1%, respectively; the PARs for the PP population were 60.3% and 76.2% at 4 and 12 weeks, respectively. Mean times to wound healing were 59

days and 56 days in the ITT and PP populations, respectively.

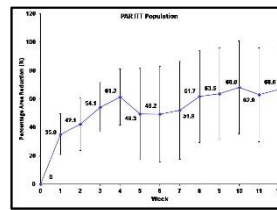


Fig. 3: Percentage area reduction for the ITT population, showing mean reduction per week with associated 95% confidence

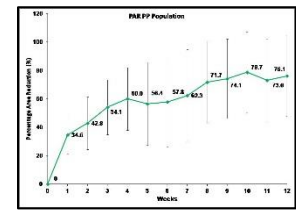


Fig. 4: Percentage area reduction for the PP population, showing mean reduction per week with associated 95% confidence

Thirty-two AEs occurred (only 2 were possibly device related). The mean AE rate for both the ITT and PP populations was 1.6.

Among the participants with healed DFUs, there was a 62-year-old man with a DFU on the right heel measuring 5.7 cm² duration of 1.8 years after failing to heal following multiple treatments. The following products and procedures were previously applied to this wound without success: gauze, absorption foam, calcium alginate, silver alginate, saline irrigation, surgical debridement, sharp debridement, autologous skin graft (CELLUTOME; Acelity, San Antonio, TX), collagen dressing, and hyperbaric oxygen therapy (HBOT). After the blood clot product was applied to the ulcer, it was completely healed at day 78 (Figure 5B).

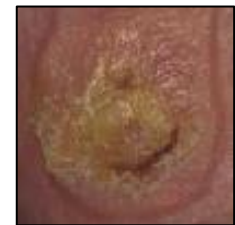
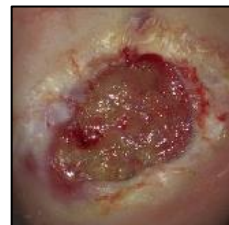
Fig. 5: (A) a 5.7 cm² Texas grade 2a diabetic foot ulcer with a duration of 1.8 years on the heel of a 62-year old male is shown on day 1. (B): The same ulcer is shown completely closed on day 78.

Conclusions. The RD1 was safe and efficacious in treating a sample of patients with UT grade 1A and 2A neuropathic DFUs, a substantial proportion (n = 9; 45%) of which had a duration of at least 6 months and 25% (n = 5) had a duration of >1 year, and many had been previously treated with advanced therapies without success. Furthermore, there was a mean number of 8.8 comorbidities per participant, and participants were taking a mean of 9.9 medications, indicating their poor health status, which could have delayed wound healing. Nevertheless, nearly two-thirds of DFUs in the total study sample healed after about 8 weeks of treatment with the RD1.

Efficacy and Safety of a Autologous Blood Clot Product (RD1) in the Management of Complicated, Chronic Wounds: A Pilot Study

Author(s): ¹Igal Kushnir, MD; ¹Alon Kushnir; ²Thomas E. Serena, MD; and ³Doron Garfinkel, MD

Affiliations: RedDress Ltd, Pardes Hanna, Israel; Clinical Research, Serena Group Wound and Hyperbaric Centers, Warren, PA; and Homecare Service, Israel Cancer Association and Geriatric-Palliative Service, Wolfson Medical Center, Holon, Israel

Objective. This pilot study evaluated the efficacy and safety of a novel method using an autologous whole blood clot formed with the RedDress Wound Care System (RD1, RedDress Ltd, Israel), a provisional whole blood clot matrix used in the treatment of chronic wounds of various etiologies.

Methods and Materials. Patients were treated at the bedside with the RD1. Blood was withdrawn from each patient using citrate, mixed with a calcium gluconate/kaolin suspension, and injected into an RD1 clotting tray. Within 10 minutes, a clot was formed, placed upon the wound, and fixed with primary and secondary dressings. Wounds were redressed weekly with the RD1. Treatment was terminated when complete healing was achieved, or when the clinician determined that the wound could not further improve without additional invasive procedures.

Results. Seven patients with multiple and serious comorbidities and 9 chronic wounds were treated with 35 RD1. Complete healing was achieved in 7 of 9 wounds (78%).

In Figure 1A, a before and after example of complete healing in a pressure ulcer on the sacrum of a bedridden, 90-year-old female patient with Huntington's disease, severe dementia, chronic anemia, and lipidemia. In figure 1B, complete closure was achieved after 50 days with 7 RD1 applications.

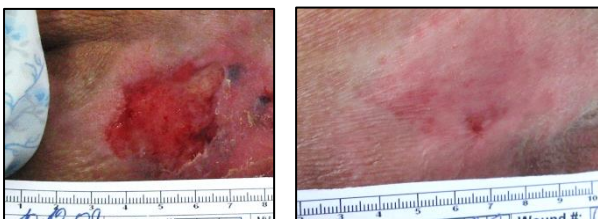


Figure 1: (A) A pressure ulcer on the sacrum with an initial area of 6.6 cm². (B) Complete healing achieved after 7 RD1 applications on Day 50

In Figure 2A, a pressure ulcer on the left heel of a bedridden, 90-year-old male patient with similar multiple comorbidities is shown measuring at 4.7 cm² prior to the RD1 treatment. In Figure 2B, the ulcer is shown completely healed after 49 days with 7 applications.

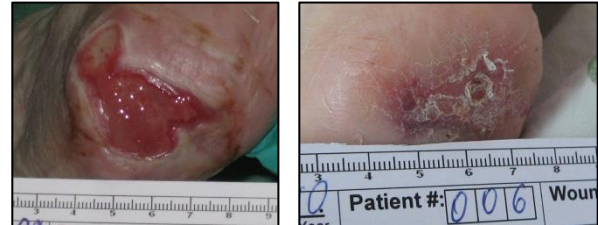


Figure 2: (A) A pressure ulcer on the left heel with an initial area of 4.7 cm² (B) Complete healing achieved after 7 RD1 applications on Day 49.

In 1 venous ulcer with a nonhealing fistula, 77% healing was achieved. Treatment was terminated in 1 pressure ulcer at 82% closure, because an unexpected mechanical trauma resulted in deterioration; this was the only adverse event reported, unrelated to the product. No systemic adverse events occurred.

Most treatment periods lasted 7 to 61 days, with 1 to 7 applications required. Treatment lasted 7 to 50 days on wounds with complete closure. Only a single RD1 application was needed in 4 wounds (ie, 2 venous ulcers, a tear wound, and a middle finger tip amputation). The range of applications was 1–7 with a mean of 3.9 applications per wound on average every 8.3 days.

In figure 3A, a skin tear on the left shin in a 93 years old female patient measuring at 28.1 cm² prior to the RD1 treatment. Patient undergone only 1 RD1 application. In figure 3B, the wound covered with a 14 days old RD1. In figure 3C, the wound after removal of 21 days old RD1.

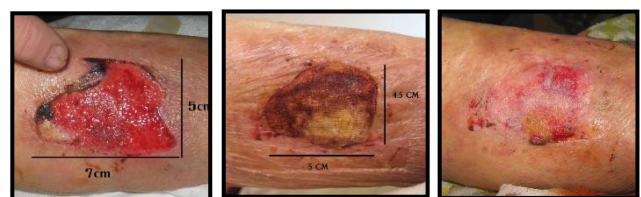

Figure 3: (A) A skin tear on the shin with an initial area of 28.1 cm². (B) 14 days old RD1 covering the wound. (C) Complete healing achieved after 1 RD1 applications on Day 21

Conclusions. This pilot study demonstrates the RD1 autologous whole blood clot matrix is effective and safe for treating patients with chronic wounds of different etiologies. A larger clinical trial is needed to assess the relative success rate of the matrix in different types of wounds in a diverse population with comorbidities.